

Outbreaks of Disease Possibly Due to a Natural Avian Herpesvirus Infection in a Colony of Young Magnificent Frigatebirds (*Fregata magnificens*) in French Guiana

Benoit de Thoisy,^{1,2,6} Anne Lavergne,¹ Julien Semelin,³ Jean-François Pouliquen,¹ Fabian Blanchard,⁴ Eric Hansen,⁵ and Vincent Lacoste¹ ¹Laboratoire des Interactions Virus-Hôtes, Institut Pasteur de la Guyane, 23 Avenue Pasteur, F-97300 Cayenne, French Guiana; ²Association Kwata "Study and Conservation of Guianan Wildlife", 16 Avenue Pasteur, F-97300 Cayenne, French Guiana; ³Réserve naturelle de l'île du Grand Connétable, 15 Lotissement Massel, F-97300 Cayenne, French Guiana; ⁴Ifremer, Laboratoire Ressources Halieutiques, BP 477, F-97300 Cayenne, French Guiana; ⁵Office National de la Chasse et de la Faune Sauvage, 23 Rue des Améthystes, F-97300 Kourou, French Guiana; ⁶Corresponding author (email: bdehoisy@pasteur-cayenne.fr)

ABSTRACT: The Ile du Grand Connétable nature reserve is a rocky island off the Northern Atlantic coast of South America that hosts a unique population of Magnificent Frigatebirds (*Fregata magnificens*, Pelecaniformes). A high chick mortality, associated with nodular proliferative lesions, involving featherless areas, such as legs, neck, eyelids, and beak, was recorded during a consecutive 2 yr and affected almost half of the generation. Investigations were, therefore, conducted to determine the cause of these epidemics. Although histopathologic investigations suggested that malnutrition, because of fewer resources in the Frigates' fishing area, could be the cause of the epidemic, a novel alphaherpesvirus, tentatively called *Fregata magnificens* herpesvirus, was detected in cutaneous crusts on the diseased birds. Although in this study, we do not prove the causal link of this new virus to the symptoms observed, it can nevertheless be suggested that in debilitated hosts, a productive herpesvirus infection might accelerate, and/or be accelerated by, population declines. These results emphasize the need to take into consideration the possible role of herpesviruses in weakened populations of wild birds in conservation management plans.

Key words: Alphaherpesvirus, chick mortality, *Fregata magnificens*, Frigatebird.

Mortality outbreaks in wild bird populations are mainly related to acute or chronic pollution and infectious diseases, and these epidemic events have increasing impacts on population conservation (Daszak et al., 2001; Wellehan et al., 2003). Among viruses, herpesvirus infection has been widely reported in wild bird populations for decades; these diseases are

among the most common health problems in aquatic birds, parrots, and passerines (Johnson and Tyack, 1995; Converse and Kidd, 2001; Tomaszewski et al., 2001; Newman et al., 2007). Herpesvirus infections have also been reported in vultures, falcons, wild turkeys, penguins, and ducks (Grant et al., 1975; Kincaid et al., 1988; Wojcinski et al., 1991; Forbes et al., 2000; Cardoso et al., 2005).

The Ile du Grand Connétable nature reserve (4°49'30"N, 51°56'00"W) is a rocky island located off the Northern Atlantic coast of South America that hosts a unique population of Magnificent Frigatebirds (*Fregata magnificens*, Pelecaniformes). With about 5% of the Caribbean population, this Frigatebird colony is one of the most important of the region, and the sole nesting site between the islands of Tobago and Fernando do Noronha (Dujardin and Tostain, 1990). In July 2005, after the annual hatching period, 25 dead chicks were found, and 30 live chicks among the 250 nests on the island had clinical cutaneous signs. Nodular proliferative lesions involving featherless areas, such as legs, neck, eyelids, and beaks, and keratitis and conjunctivitis were present (Fig. 1). Dead and affected birds were not geographically restricted but widespread over the entire island, in proximity to healthy animals. Clinical signs or lesions were not observed in adults or other avian species present on the island (*Sterna*



FIGURE 1. Skin lesions and cornea alteration in a Frigatebird chick.

maxima, *Sterna eurygnatha*, *Sterna fuscata*, *Anous stolidus*, and *Larus atricilla*). In the following 2 wk, 33 more dead chicks were recorded, and 27 chicks had clinical signs. After 1 mo, 41 additional dead chicks were recorded. Through intense monitoring of nests, it was confirmed that symptoms were always lethal: no animal with clinical signs recovered.

In sampled animals, we observed thickening of the skin, hyperkeratosis, bone frailty, and severe emaciation. Blood samples were collected from 11 chicks, five from healthy animals and six from animals with clinical signs. In addition, skin samples from three of six affected birds were collected and preserved in Hanks medium. One dead animal was submitted for necropsy. Clinical pathologic findings included marked hypophosphatemia (1.78 mmol/l, $n=4$, vs. 4.03 mmol/l in healthy chicks, Work 1996), whereas calcemia, hematocrit and hemoglobin measurements were within

reference range values (Work, 1996). No inflammatory lesions were seen during histopathologic examination of the esophagus, intestine, and trachea. Lungs were moderately congested, and muscles had a slight interstitial edema. The liver had minor perivascular inflammatory infiltrates, and the kidneys had two foci of interstitial inflammatory cells. Bone mineralization was deficient, with a thin primary ossification area and persistent cartilage. Finally, dermal tissues had hyperkeratosis, and epidermal keratinocytes had ballooning degeneration, but no inflammatory process or intranuclear viral inclusions were observed. These findings are typical of a poor nutritional status. Bacterial cultures and microscopic evaluation of skin samples excluded the possibility of a bacterial infection and the presence of ectoparasites. The birds were negative for avian poxvirus DNA, as determined by polymerase chain reaction (PCR), using previously published procedures (Kim et al., 2003).

We attempted to amplify herpesviral sequences using a nested PCR (nPCR) approach, with degenerate consensus primers targeted to highly conserved amino acid motifs within the herpesvirus DNA polymerase gene (Rose et al., 1997). Amplification products of the expected size (about 250 base pair [bp]) were identified in one skin sample, and these products were sequenced after cloning. Database searches using the Basic Local Alignment Search Tool (BLAST) Web server revealed the presence of a new herpesvirus sequence. To extend the nucleotide sequence upstream, a specific, nondegenerate oligonucleotide was designed from the complementary sequence of the small fragment and was used in an nPCR amplification with the DFASA primer pool (Lacoste et al., 2000). The PCR products from the initial PCR were used as template DNA in the subsequent amplification reactions. The upstream nPCR products were subsequently cloned and sequenced. The resulting sequences were assembled to give a total of 476 bp (excluding primers). The obtained consensus was deposited in GenBank under accession number EU867220. BLAST searches showed that this novel sequence was most similar to the DNA polymerases of the *Alphaherpesvirinae* subfamily. Comparison of amino acid identities among alphaherpesviruses indicated that the Frigatebird herpesvirus, tentatively named FmagHV for *Fregata magnificens* herpesvirus, was most closely related to the Vulture herpesvirus (VHV), exhibiting 83.5% identity (Cardoso et al., 2005). Furthermore, within the *Alphaherpesvirinae* subfamily, our Frigatebird herpesvirus sequence was more closely related to the human herpes simplex virus types 1 and 2 (HSV-1 and HSV-2) of the simplex genus (81.4 and 79.7% amino acid identity, respectively) than to the other bird alphaherpesviruses (73% of amino acid identity with Marek's disease virus type 2 and 65% with Psittacid herpesvirus 1 and Passerine herpesvirus 1). Phylogenetic

analyses were performed on 124 amino acids. The amino acid sequence was aligned using ClustalW (European Molecular Biology Laboratory, European Bioinformatics Institute, Hinxton, Cambridge, UK; Thompson et al., 1994) with other previously published sequences, and alignments were checked manually. The ProtTest program (Abascal et al., 2005) was used to determine the optimal model of amino acid evolution for the data set. A Bayesian approach was performed with the program BEAST version 1.4.7 (Drummond and Rambaut, 2007) to infer phylogenetic relationships. Analysis was performed using a WAG model of amino acid substitutions with a gamma distributed rate of variation among sites and six rate categories. We ran the analysis assuming a constant population size and a relaxed molecular clock (uncorrelated lognormal). Results from the run (10,000,000 generations with the first 1,000,000 discarded as burn-in and parameter values sampled every 100 generations) were analyzed using the program Tracer version 1.4 (Rambaut and Drummond, 2003). The phylogenetic analysis placed the Frigatebird herpesvirus (FmagHV) close to the VHV with a posterior probability value of 1. This cluster is associated with the *simplex* genus encompassing HSV-1, HSV-2, Cercopithecine herpesvirus 1 and 2 (CeHV-1 and CeHV-2), as well as bovine herpesvirus 2 (BoHV-2) with less support (0.76; Fig. 2).

In poultry or in captive avian species, symptoms of herpesviral infections are diverse. They are associated with different diseases, such as Marek's disease, duck viral enteritis, infectious laryngotracheitis, and Pacheco's disease. Pacheco's disease has no evident clinical signs in parrots, and some animals may recover (Tomaszewski et al., 2001). In passerines, clinical signs are mainly respiratory, with or without conjunctivitis (Wellehan et al., 2003). In wild bird populations, it has been suggested that herpesvirus outbreaks are often facilitated by immune suppression of

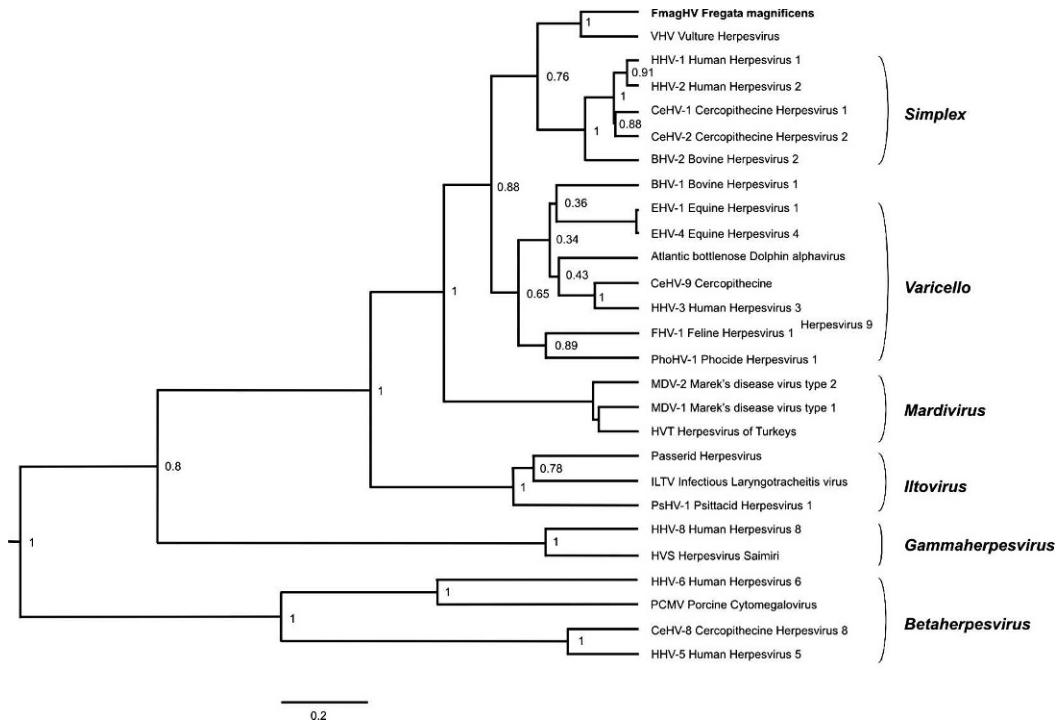


FIGURE 2. Phylogenetic tree (based on 124 amino acid sequences of the DNA polymerase gene, using a Bayesian procedure) showing relationships between *Fregata magnificens* herpesvirus and other selected herpesviruses.

animals resulting from polluted environments (Goldberg et al., 1990). Nevertheless, despite an impressive number of clinical cases recorded, molecular investigations have rarely been conducted during herpesvirus outbreaks. The particular outbreaks as well as the virus we described in this Frigatebird colony thus raised two major questions. First, concerning the immune status of the target population, there is no existing indication of immune suppression in these birds. Although there are no records of marine pollution in the nature reserve, Magnificent Frigatebirds cover an average of 223 km per foraging trip (Weimerskirch et al., 2003). It is possible that birds could be contaminated far from the site of the outbreak. Because clinical signs were restricted to juveniles, an immune deficiency due to malnutrition could also be advocated. Frigatebirds often feed on refuse from fishing ships, with more than 120 Frigatebirds frequently observed

on a single trawler (Calixto-Albarran and Osorno, 2000). In French Guiana, activities associated with the industrial shrimp trawling fisheries had decreased 1 mo before the appearance of the first chick symptoms and may have resulted in malnutrition. The observed biochemistry changes and clinical signs, such as hypocalcemia, hypophosphatemia, and hyperkeratosis, support this supposition. Second, the origin of the virus is unknown. It has been suggested that migratory birds could facilitate herpesvirus dissemination (Hubalek, 2004; Newman et al., 2007), especially related to cross-species infections. The herpesvirus sequence that we isolated in Frigatebird tissues may have originated from a different avian species; however, the natural host range of most herpesviruses is highly restricted (Davison, 2002). Herpesviruses are highly adapted to their hosts, and in these hosts, severe infections are usually restricted to very young or immunosuppressed individuals.

For this reason, we believe that the virus characterized here is very likely indigenous to Frigatebirds, and the sequence reported in the present study is unique, supporting this hypothesis. In this study, we do not prove the causal link between this virus and the outbreaks; the classic herpetic viral inclusion bodies and associated dermatitis were not observed, and histologic changes were more likely related to malnutrition. The virus was only identified in skin lesions, suggesting that it might be reactivated, and that it might, therefore, interact with host fitness. Our results thus suggest that, in a context of debilitated hosts, productive herpesvirus infection might accelerate and/or be accelerated by population declines. The possible role of herpesviruses in weakened populations of wild birds, therefore, should be considered in conservation plans (Cardoso et al., 2005).

Investigations were funded by the Laboratoire des Interactions Virus-Hôtes, Institut Pasteur de la Guyane, by the French Guiana's Regional Environmental Authority (DIREN), and by the French Space Agency (CNES) under a State-Region Planning Contract/Single Programming Document (CPER/DocUP). We are grateful to French Guiana's Department of Veterinary Services, H. Morvan (Veterinary Research Laboratory on Poultry and Swine, Ploufragan, France), O. Chastel (Chizé Center for Biological Studies, CNRS, France), J. M. Péricard (Association of Avian Veterinarians), and M. L'Hostis (National Veterinary School, Nantes, France) for discussions on the clinical cases and diagnosis.

LITERATURE CITED

- ABASCAL, F., R. ZARDOYA, AND D. POSADA. 2005. ProtTest: Selection of best-fit models of protein evolution. *Bioinformatics* 21: 2104–2105.
- CALIXTO-ALBARRAN, I., AND J. L. OSORNO. 2000. The diet of the Magnificent Frigatebird during chick rearing. *Condor* 102: 569–576.
- CARDOSO, M., A. HYATT, P. SELLECK, S. LOWTHER, V. PRASKASH, D. PAIN, A. A. CUNNINGHAM, AND D. BOYLE. 2005. Phylogenetic analysis of the DNA polymerase gene of a novel alphaherpesvirus isolated from an Indian *Gyps* Vulture. *Virus Genes* 30: 371–381.
- CONVERSE, K. A., AND G. A. KIDD. 2001. Duck plague epizootics in the United States, 1967–1995. *Journal of Wildlife Diseases* 37: 347–357.
- DASZAK, P., A. A. CUNNINGHAM, AND A. D. HYATT. 2001. Anthropogenic environmental change and the emergence of infectious diseases in wildlife. *Acta Tropica* 78: 103–116.
- DAVISON, A. J. 2002. Evolution of the herpesvirus. *Veterinary Microbiology* 86: 69–88.
- DRUMMOND, A. J., AND A. RAMBAUT. 2007. BEAST: Bayesian evolutionary analysis by sampling trees. *BMC Evolution Biology* 7: 214.
- DUJARDIN, J. L., AND O. TOSTAIN. 1990. Les oiseaux de mer nicheurs de Guyane Française. *Alauda* 58: 107–134. [In French.]
- FORBES, N. A., S. HIGSTON, AND P. ZSIVANOVITS. 2000. Falcon herpesvirus in the UK. *Veterinary Records* 147: 492.
- GOLDBERG, D. R., T. M. YUILL, AND E. C. BURGESS. 1990. Mortality from duck plague virus in immunosuppressed adult mallard ducks. *Journal of Wildlife Diseases* 26: 299–306.
- GRANT, H. G., K. D. LEY, AND C. F. SIMPSON. 1975. Isolation and characterization of a herpesvirus from wild turkeys (*Meleagris gallopavo osceola*) in Florida. *Journal of Wildlife Diseases* 11: 562–565.
- HUBALEK, Z. 2004. An annotated checklist of pathogenic microorganisms associated with migratory birds. *Journal of Wildlife Diseases* 40: 639–659.
- JOHNSON, M. A., AND S. G. TYACK. 1995. Molecular evolution of infectious laryngotracheitis virus (ILT; Gallid herpesvirus 1): an ancient example of the *Alphaherpesviridae*? *Veterinary Microbiology* 46: 221–231.
- KIM, T. J., W. M. SCHNITZLEIN, D. MCALOOSE, A. P. PESSIER, AND D. N. TRIPATHY. 2003. Characterization of an avianpox virus isolated from an Andean Condor (*Vultur gryphus*). *Veterinary Microbiology* 96: 237–246.
- KINCAID, A. L., T. E. BUNTON, AND M. CRANFIELD. 1988. Herpesvirus-like infection in Black-Footed Penguins (*Spheniscus demersus*). *Journal of Wildlife Diseases* 24: 173–175.
- LACOSTE, V., P. MAUCLERE, G. DUBREUIL, J. LEWIS, M. C. GEORGES-COURBOT, J. RIGOLET, T. PETIT, AND A. GESSAIN. 2000. Note: Simian homologues of human gamma-2 and betaherpesviruses in mandrill and drill monkeys. *Journal of Virology* 74: 11993–11999.
- NEWMAN, S. H., A. CHMURA, K. CONVERSE, A. M. KILPATRICK, N. PATEL, E. LAMMERS, AND P. DASZAK. 2007. Aquatic bird disease and mortality as an indicator of changing ecosystem health. *Marine Ecology Progress Series* 352: 299–309.

- RAMBAUT, A., AND A. J. DRUMMOND. 2007. Tracer. Version 1.4. <http://beast.bio.ed.ac.uk/Tracer>. Accessed March 2008.
- ROSE, T. M., K. B. STRAND, E. R. SCHULTZ, G. SCHAEFER, G. W. RANKIN, JR., M. E. THOULESS, C. C. TSAI, AND M. L. BOSCH. 1997. Identification of two homologs of the Kaposi's sarcoma-associated herpesvirus (human herpesvirus 8) in retroperitoneal fibromatosis of different macaque species. *Journal of Virology* 71: 4138–4144.
- THOMPSON, J. D., D. G. HIGGINS, AND T. J. GIBSON. 1994. Clustal W: Improving the sensitivity of progressive multiple sequence alignment through sequence weighting, position-specific gap penalties and weight matrix choice. *Nucleic Acids Research* 22: 4673–4680.
- TOMASZEWSKI, E., G. WILSON, W. L. WIGLE, AND D. N. PHALEN. 2001. Detection and heterogeneity of herpesviruses causing Pacheco's disease in parrots. *Journal of Clinical Microbiology* 39: 533–538.
- WEIMERSKIRCH, H., O. CHASTEL, C. BARBRAUD, AND O. TOSTAIN. 2003. Frigate birds ride high on thermals. *Nature* 421: 333–334.
- WELLEHAN, J. F. X., M. GAGEA, D. A. SMITH, W. M. TAYLOR, Y. BERHANE, AND D. BIENZLE. 2003. Characterization of a herpesvirus associated with tracheitis in Gouldian Finches (*Erythrura [Chloebia] gouldiae*). *Journal of Clinical Microbiology* 41: 4054–4057.
- WOJCINSKI, Z. W., H. S. J. WOJCINSKI, I. K. BARKER, AND N. W. KING. 1991. Cutaneous herpesvirus infection in a Mallard Duck (*Anas platyrhynchos*). *Journal of Wildlife Diseases* 27: 129–134.
- WORK, T. M. 1996. Weights, hematology, and serum chemistry of seven species of free-ranging tropical pelagic seabirds. *Journal of Wildlife Diseases* 32: 643–657.

Received for publication 11 July 2008.